

Trauma Wound with Tissue Loss

A case study by Craig S. Walvatne, MD
Vascular Surgery Associates
Coon Rapids, MN

CASE STUDY: UNITE® BIOMATRIX XENOGRAFT USED IN SUCCESSFUL HEALING OF A LARGE TRAUMATIC WOUND WITH TISSUE LOSS

Unite® Biomatrix from Synovis Orthopedic & Woundcare, Inc. is a highly organized, non-reconstituted xenograft for the management of wounds. A variety of factors contribute to the nature of a chronic wound bed, including elevated levels of matrix metalloproteinases (MMP's) which inhibit normal healing. Flexibly crosslinked and sterilized* using proprietary technologies, Unite® Biomatrix is able to resist premature degradation caused by these elevated levels of MMP's**. Clinical results suggest that this xenograft helps maintain the wound bed in the healing phase to allow for healthy granulation tissue and wound closure. Unite® Biomatrix is safe, biocompatible, allows for reliable fixation to the wound perimeter, and has a four-year, room temperature shelf-life.

ABSTRACT

A 76 year old female presented to her local hospital with a lacerated left anterior shin. The wound was closed in the emergency room, however, over the following two weeks she noted a discoloration of the wound site associated with drainage from the wound and discomfort. The patient was seen in the wound clinic two weeks following her initial presentation at the emergency room. At this time a large amount of necrotic tissue was sharply debrided from the wound and venous insufficiency was diagnosed by ultrasound. Conservative therapy with compression and topical antimicrobial care (initially silver sulfadiazene, later silver alginate) was used for six weeks with little improvement. To stimulate healing response, it was decided the patient would be taken to the OR to apply Unite® Biomatrix xenograft. Despite a required saphenous vein ablation at 18 weeks post-xenograft application, the wound healed in 22 weeks with no recurrent ulceration to that site.

PATIENT HISTORY

The patient's medical history included: Type 2 diabetes, hypertension, hypercholesterolemia, obesity and venous insufficiency (new diagnosis).

PHYSICAL EXAM

Left leg with edema controlled with compression. Left lateral shin ulcer with granulation tissue, no slough, measuring 6cm x 2.8cm x 1.3cm in largest dimensions. Palpable pedal pulses.

PROCEDURE

Patient was taken to the OR where the left leg was scrubbed, prepped and draped in the normal sterile manner. Surgical debridement of all nonviable tissue was performed under a local anesthetic and bleeding at the wound site was controlled with topical thrombin.

A fenestrated 6cm x 6cm Unite® Biomatrix was circumferentially secured to the edges of the wound using a 3-0 Prolene™ suture (Ethicon). Care was taken to ensure Unite® Biomatrix was in intimate contact with the entire wound bed and there was 1-2cm excess border beyond the wound margins. A 4-0 Monocryl™ suture (Ethicon) was used to secure the graft at two points in the center of the wound to assist secure contact to the entire wound surface. A non-adherent dressing was then applied over Unite® Biomatrix, followed by a sterile dressing. An elastic bandage was used to apply compression.

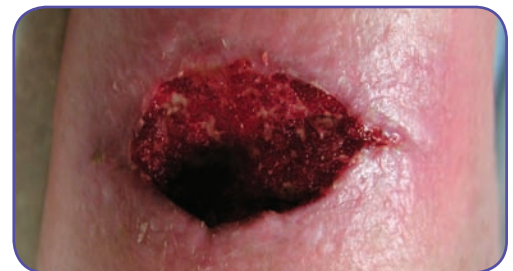

Figure 1. Initial presentation of trauma wound

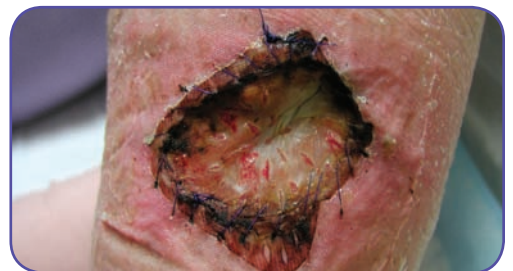

Figure 2. 1 week post-op

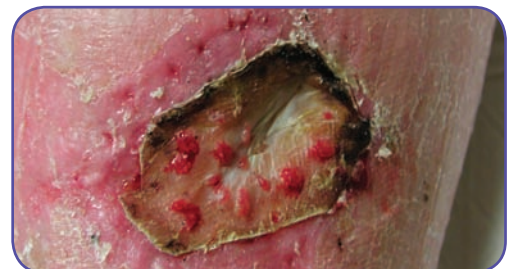

Figure 3. 3 weeks post-op

POST APPLICATION MANAGEMENT

The wound was examined weekly and the site was covered with dry gauze only. Compression was maintained using compression wraps. There was evidence of granulation tissue formation and the wound began to reduce in size. At two weeks post-application, all sutures were removed. The xenograft material that remained on the wound bed was allowed to dissociate from the wound on its own. As healing progressed, edges of Unite® Biomatrix were trimmed as needed. Measuring length, width and depth of the wound, the area reduced in size by 54% at three weeks post-application and 84% at 12 weeks post-application.

Healing was noted to have stalled at approximately 14 weeks post-application of Unite® Biomatrix. It was suspected that this may have been due to the patient's venous insufficiency and, therefore, radiofrequency ablation of the left greater saphenous vein was performed 18 weeks after the xenograft was initially applied.

Unite® Biomatrix dissociated from the wound bed during removal of the surgical dressing two weeks after the saphenous vein ablation (20 weeks post-application) and the remaining superficial wound measured 2cm x 0.3cm x 0.1cm. Complete re-epithelialization was noted at 22 weeks post-application.

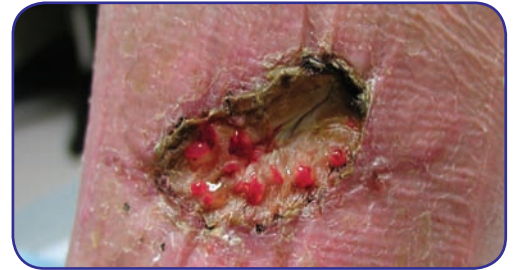


Figure 4. 5 weeks post-op.

RESULTS

Closure of the large trauma wound was accomplished 22 weeks following a single application of Unite® Biomatrix. Significant reconstitution of the tissue volume deficit by tissue re-growth was reported. The cosmetic appearance was acceptable in light of the original defect. No dressings other than dry gauze were needed after placement of the xenograft.

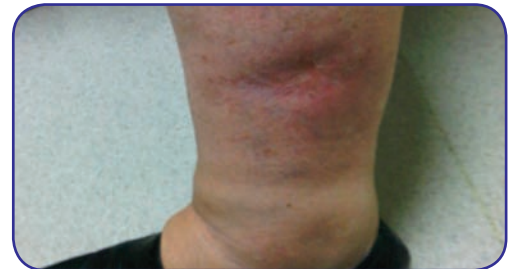

Figure 5. Final follow up. 22 weeks post-op.

DISCUSSION

Synovis Orthopedic and Woundcare's novel stabilization and sterilization technologies are new to advanced wound management. Unite® Biomatrix easily conforms to the wound bed and resists premature enzymatic breakdown. This case study demonstrates the successful clinical use of a xenograft for a traumatic wound in a patient with venous insufficiency and diabetes. This technique can be used as an effective solution to achieve healing of difficult wounds in patients with complicated comorbidities.

A case study by Craig S. Walvatne, MD, Vascular Surgery Associates, Coon Rapids, MN

For additional information and/or product support, please contact your local Synovis Orthopedic & Woundcare representative or Customer Service at 1-800-650-1816.

* Passes USP Sterility Testing. Data on file.

** Data on file. Synovis Orthopedic & Woundcare Inc.

Refer to the Synovis Orthopedic & Woundcare, Inc. Instructions for Use for the proper use, precautions, warnings, approved indications and labeling of the Unite® Biomatrix. CAUTION: Federal law restricts this product to sale by or on the order of a physician. Unite® is a registered trademark of Synovis Orthopedic & Woundcare, Prolene™ and Monocryl™ are trademarks of Ethicon, Inc.

©2011 Synovis Orthopedic & Woundcare, Inc. All rights reserved. SAM-0236 Rev A (11/11)

Synovis®

Orthopedic and Woundcare, Inc.

6 Jenner, Suite 150, Irvine, CA 92618 USA
Phone: 800.650.1816 Fax: 949.502.3245
www.synovisorthowound.com



Authorized Representative
in the European Community:
AR-MED
Runnymede Malthouse
Egham TW20 9BD
United Kingdom

