

Distal Biceps Tendon Repair

A Case Study by Stelios Maheras, MD, Metropolitan Hospital, Athens, Greece

CASE STUDY: DISTAL BICEPS TENDON REPAIR WITH ORTHADAPT® BIOIMPLANT REINFORCEMENT

The OrthADAPT® Bioimplant from Synovis Orthopedic & Woundcare, Inc. is a highly organized collagen scaffold that can be used for implantation to reinforce the repair or reconstruction of soft tissues. The collagen scaffold is flexibly crosslinked and sterilized* using proprietary technologies which make it resistant to premature enzyme degradation, biocompatible and safe. The OrthADAPT® Bioimplant allows for a stronger repair over time and the potential for minimal pain and swelling.

ABSTRACT

A male with an acute right distal biceps tendon rupture underwent surgery for the repair and reattachment of the distal biceps. An OrthADAPT® Bioimplant was wrapped 270° around the biceps tendon to augment the repair and enhance biologic healing.

PATIENT HISTORY

A 49 year old right hand dominant male suffered an acute right distal biceps tendon rupture after his flexed arm was forced to straighten under sudden force. The patient felt a “pop” and reported swelling in the forearm. There was also visible deformity of the biceps muscle. The patient reported weakness with flexion and supination of the arm.

Physical examination revealed a retracted distal biceps tendon that was palpable 11 cm proximal to the antecubital fossa. MRI confirmed the distal biceps rupture. The patient elected to have surgery due to his young age and active lifestyle.

PROCEDURE

The surgery was performed under general anesthesia in supine position with the extremity on an arm board. A tourniquet was not used. A curvilinear incision was made near the rupture site. After incising the deep fascia, blunt dissection was used to identify the radial tuberosity. Care was taken to avoid injury to the lateral antebrachial cutaneous nerve. The tendon stump, which was proximally retracted, was identified and #5 Ethibond® suture was passed through the tendon. All damaged and degenerative tissue was debrided from both tendon ends prior to suturing.

It was decided to augment the repair with an OrthADAPT® Bioimplant from Synovis Orthopedic & Woundcare, Inc. A 2 cm x 15 cm bioimplant was prepared in the prescribed manner. With traction on the biceps tendon, the bioimplant was wrapped 270° and secured around its periphery using #2 Ethibond® non-absorbable suture. Care was taken to apply maximum tension to the OrthADAPT® Bioimplant while suturing to create a low profile repair and to maximize contact with the tendon. This new construct was then ready to be passed through a transosseous tunnel and secured.

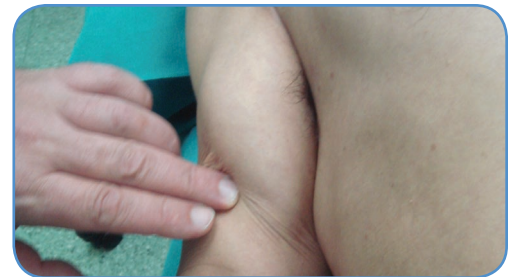

Figure 1. Visible deformity of the biceps muscle

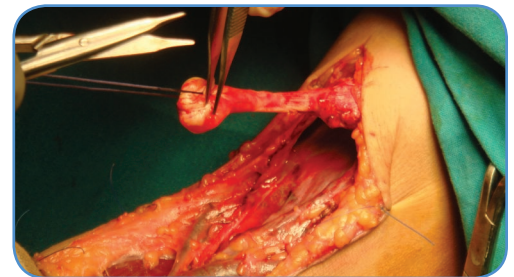


Figure 2. Initial suturing of retracted tendon.

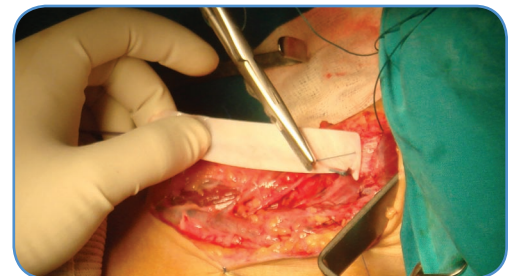

Figure 3. Initial suturing of the OrthADAPT® Bioimplant.

Distal Biceps Tendon Repair

A Case Study by Stelios Maheras, MD, Metropolitan Hospital,
Athens, Greece

The arm was maximally pronated and a curved hemostat was passed through the biceps tendon sheath and down towards the radius and the ulna. The hemostat was then passed through the common extensor muscles until palpable under the subcutaneous tissue, marking where the dorsal lateral incision was to be made. The radial tuberosity was exposed and an osteotome was used to prepare the tuberosity for reattachment of the tendon. Several suture holes were drilled into the radial aspect of the tuberosity. This area was then irrigated appropriately. The #5 Ethibond® suture limbs were used to pull the biceps tendon through this distal incision. The sutures were passed through the tuberosity and secured to the radius. Elbow range of motion was tested from 30° to 130° and the fixation was found to be stable. The incisions were closed in layers and the elbow was placed in a splint at 90° of flexion and 45° supination.

RESULTS

- Excellent reinforcement of the biceps tendon was achieved with the use of the OrthADAPT® Bioimplant.
- 16 months post-op the patient enjoys active daily living with full range of motion in the biceps tendon.
- No operative or post-operative complications were experienced.

DISCUSSION

The OrthADAPT® Bioimplant is a versatile collagen scaffold which provides excellent augmentation and strength for biceps tendon repair. The thinness and conformity of the OrthADAPT® Bioimplant contributed to the success of this procedure.

*A Case Study by Stelios Maheras, MD, Head of Sports Medicine Department,
Metropolitan Hospital, Athens, Greece*

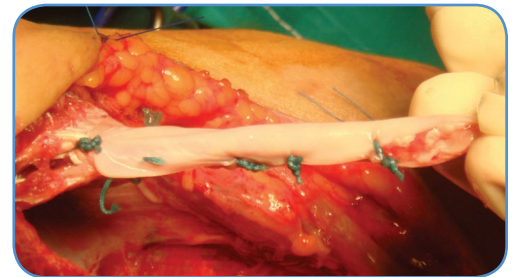


Figure 4. Suturing 270° wrap of OrthADAPT® Bioimplant.

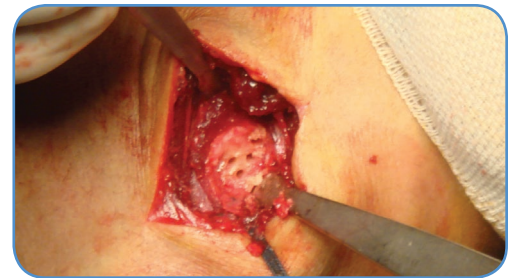

Figure 5. Drill holes in radial aspect of tuberosity.

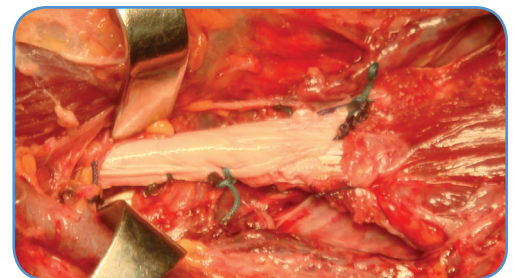
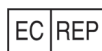
Figure 6. Completed repair of biceps tendon using the OrthADAPT® Bioimplant.

Synovis®

Orthopedic and Woundcare, Inc.

6 Jenner, Suite 150, Irvine, CA 92618 USA
Phone: 800.650.1816 Fax: 949.502.3245
www.synovisorthowound.com



Authorized Representative
in the European Community:
AR-MED
Runnymede Malthouse
Egham TW20 9BD
United Kingdom



For additional information and/or product support, please contact your local Synovis Orthopedic & Woundcare representative or Customer Service at 1-800-650-1816.

*Passes USP Sterility Testing. Data on file: Synovis Orthopedic & Woundcare, Inc. Refer to the Synovis Orthopedic & Woundcare, Inc. Instructions for Use for the proper use, precautions, warnings, approved indications and labeling of the OrthADAPT® Bioimplant. CAUTION: Federal law restricts this product to sale by or on the order of a physician. OrthADAPT® Bioimplant is a registered trademark of Synovis Orthopedic & Woundcare, Inc. Ethibond® is a registered trademark of Ethicon, a Johnson & Johnson company.

©2009 Synovis Orthopedic & Woundcare, Inc. All rights reserved. SAM0133 Rev B (09/09)